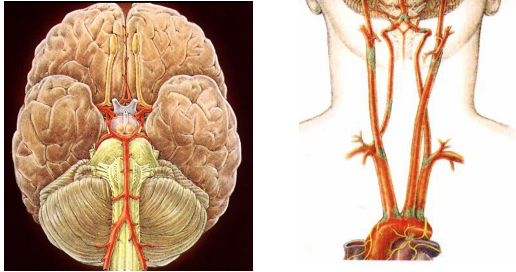
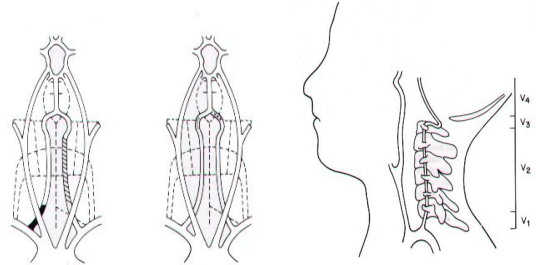


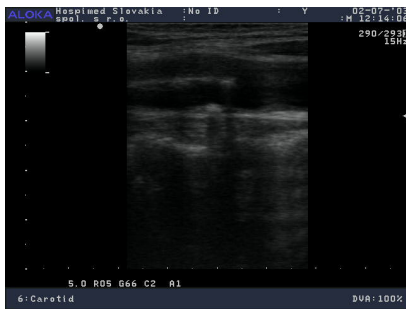
Anatomy of cerebral circulation



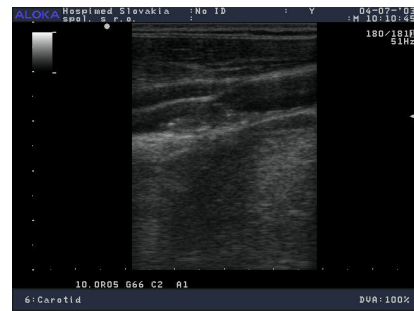Anatomy



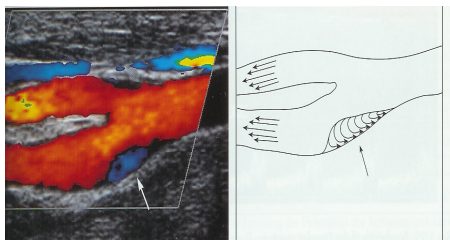
B-scan karotid bifurcation



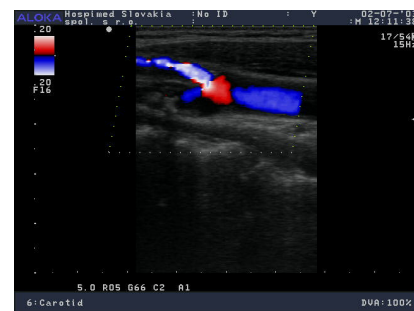
B-scan karotid bifurcation



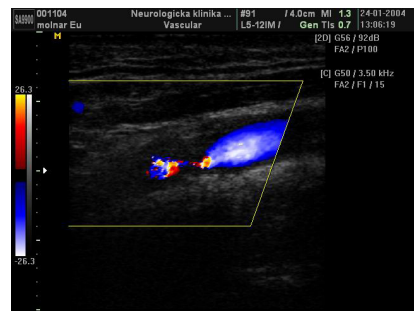
B-scan karotid bifurcation



B-scan karotid bifurcation



B-scan karotid bifurcation



Duplex ultrasound B-scan + Doppler

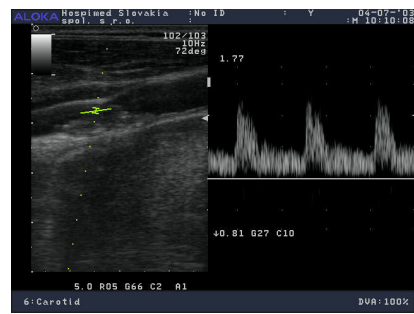

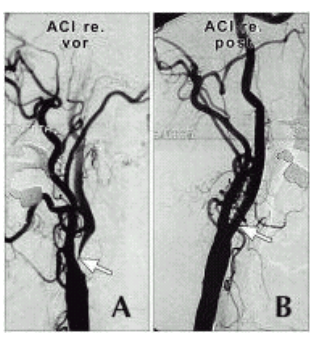
TABLE 14 INTERNAL CAROTID STENOSIS

Stenosis %	Peak Systolic Velocity	Blood flow	End Diastolic Velocity
≤ 50%	≤ 120 cm/s	Laminar	≤ 90 cm/s
51-70%	120-140 cm/s	Turbulent	≤ 90 cm/s
71-95%	≥ 240 cm/s	Turbulent	≥ 90 cm/s
96-99%	≤ 120 cm/s	Turbulent	≤ 90 cm/s
Occlusion	∓		∓

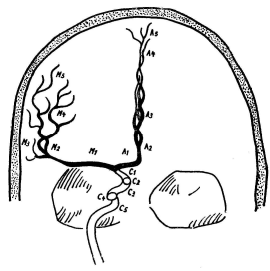
Table 15 INTERNAL CAROTID STENOSIS CLASSIFICATION

Classification according haemodynamics	Classification according degree of stenosis	Classification according % reduction of lumen
Haemodynamics is not influenced	Light stenosis	≤ 50%
	Influenced haemodynamics	
	Mild stenosis	51-70%
	Moderate stenosis	71-95%
	Severe stenosis	96-99%
Occlusion	Occlusion	Occlusion

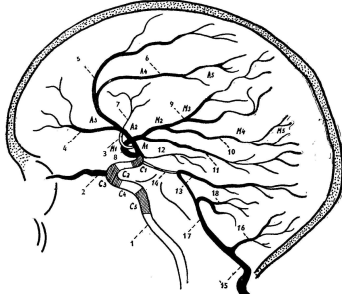
Angiography



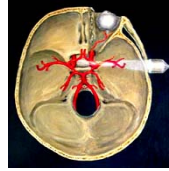
Angiography



Angiography



Transcranial doppler - TCD



- Noninvasive metod
- Measurement of cerebral arteries blood flow

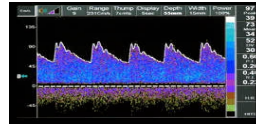
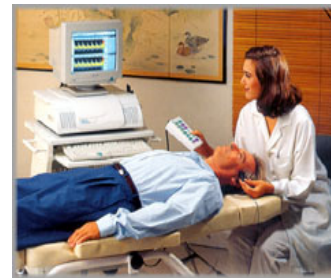

TABLE 16 IDENTIFICATION OF INTRACRANIAL ARTERIES

Artery	Transducer position	Depth of sample volume (mm)	Direction of flow
MCA	transtemporal	30-60	Toward
ACA/MCA bifurcation	Transtemporal	55-65	Bidirectional
ACA	Transtemporal	60-80	Away
PCA (P1)	Transtemporal	60-70	Toward
PCA (P2)	Transtemporal	60-70	Away
ICA	Transtemporal	55-60	Toward
OA	Transorbital	40-60	Toward
VA	Transforaminal	60-90	Away
BA	Transforaminal	80-120	Away

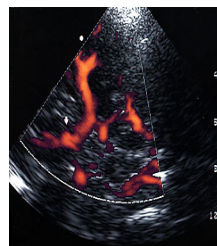
TCD



TCD a TCCS

- Indications
- Strokes
- Subarachnoid haemorrhage
- Brain death

Transkraniálny farebne kódovaný ultrazvuk - TCCS



- Noninvasive metod
- Measurement of cerebral arteries blood flow
- Visualisation of cerebral arteries